

# Visual outcomes and patient satisfaction in 9366 eyes using a refractive segmented multifocal intraocular lens

Jan A. Venter, MD, Martina Pelouskova, MSc, Barrie M. Collins, Dip.Optom (SA), PhD, Steven C. Schallhorn, MD, Stephen J. Hannan, MCOptom

**PURPOSE:** To report the effectiveness, patient satisfaction, and complication rate with a zonal refractive intraocular lens (IOL) in a high volume of patients.

**SETTING:** Private clinic, London, United Kingdom.

**DESIGN:** Case series.

**METHODS:** Retrospective data of patients with binocular Lentis Mplus IOLs were analyzed. The main outcome measures were uncorrected distance visual acuity (UDVA), uncorrected near visual acuity (UNVA), corrected distance visual acuity, manifest refraction, patient satisfaction, and complications. One-month, 3-month, and 6-month data were analyzed.

**RESULTS:** The study comprised 9366 eyes of 4683 patients. The mean spherical equivalent changed from  $+1.73$  diopters (D)  $\pm 3.37$  (SD) preoperatively to  $-0.02 \pm 0.60$  D at 3 months and  $+0.03 \pm 0.60$  D at 6 months. Ninety-five percent of patients achieved a binocular UDVA of 6/7.5 (0.1 logMAR) or better 3 months postoperatively. The mean binocular UNVA was  $0.155 \pm 0.144$  logMAR and  $0.159 \pm 0.143$  logMAR at 3 months and 6 months, respectively. Severe dysphotopsia requiring an IOL exchange occurred in 55 eyes. Patient satisfaction was high, with 97.5% of patients willing to recommend the procedure.

**CONCLUSIONS:** The zonal refractive IOL provided excellent distance and near visual acuity. The postoperative complication rate was clinically acceptable, and patient satisfaction high.

**Financial Disclosure:** Dr. Schallhorn is a consultant to Abbott Medical Optics, Inc. No author has a financial or proprietary interest in any material or method mentioned.

*J Cataract Refract Surg* 2013; ■:■–■ © 2013 ASCRS and ESCRS

The challenge for refractive surgery with multifocal intraocular lenses (IOLs) is to attain an IOL design that provides a full range of clear vision without inducing unwanted optical side effects. Several

multifocal IOL technologies have been developed.<sup>1-3</sup> These include diffractive, rotational symmetric refractive, hybrid refractive-diffractive, and pseudo-accommodating IOLs. Numerous studies<sup>4-18</sup> have confirmed these IOLs' ability to restore visual function at distance and near. However, optical side effects, such as glare, halos, and reduced contrast sensitivity, have been reported with these IOLs.<sup>19,20</sup> A new generation of IOLs with a refractive rotational asymmetry was recently developed to minimize such side effects.<sup>21-30</sup>

The aim of this study was to evaluate the clinical outcomes, visual performance, and patient satisfaction with bilateral implantation of an aspheric nonrotational symmetric multifocal IOL in a large population of patients.

Submitted: December 14, 2012.

Final revision submitted: March 26, 2013.

Accepted: March 28, 2013.

From Optical Express, London, United Kingdom.

Presented at the ASCRS Symposium on Cataract, IOL and Refractive Surgery, Chicago, Illinois, USA, April 2012.

Corresponding author: Jan A. Venter, MD, Optical Express, 22 Harley Street, London W1G 9AP, United Kingdom. E-mail: [drjanventer@googlemail.com](mailto:drjanventer@googlemail.com).

## PATIENTS AND METHODS

This retrospective study enrolled consecutive patients who had bilateral phacoemulsification followed by implantation of a Lentis Mplus IOL (Oculentis GmbH) between January 2010 and January 2012. The study cohort comprised presbyopic ametropic patients who had cataracts or were not suitable candidates for laser vision correction. All patients provided informed consent.

Exclusion criteria were a history of glaucoma or retinal detachment, corneal disease, corneal surgery, ocular inflammation, neuro-ophthalmic disease, macular degeneration or retinopathy; and keratometric cylinder greater than 1.50 diopters (D). The inclusion of amblyopic patients was restricted to those with a corrected distance visual acuity (CDVA) of 6/9 or better in the amblyopic eye and of 6/6 or better in the fellow eye.

### Patient Assessment

All patients had a preoperative examination that included autorefractometry and tonometry (Tonoref II, Nidek Co. Ltd.), corneal topography (Pentacam, Oculus, Inc.), uncorrected distance visual acuity (UDVA), CDVA, uncorrected near visual acuity (UNVA), endothelial cell count (SP 2000P specular microscope, Topcon Europe BV), biometry (IOLMaster, Carl Zeiss Meditec AG), subjective and cycloplegic refractions, slitlamp evaluation, and dilated funduscopy. Visual acuity was measured at distance with a Snellen visual acuity chart and at near with a logarithmic near visual acuity chart (Early Treatment Diabetic Retinopathy Study). Near visual acuity was recorded in Snellen distance equivalent (meters). The reading chart had a 40 cm cord attached to it to ensure that the correct reading distance was measured.

Data (axial length [AL], anterior chamber depth, and keratometry) from the IOLMaster were used for IOL calculation. The Haigis formula was used in eyes with an AL of 26.0 mm or less and the SRK/T formula<sup>31</sup> in eyes with an AL greater than 26.0 mm. All eyes were targeted for emmetropia.

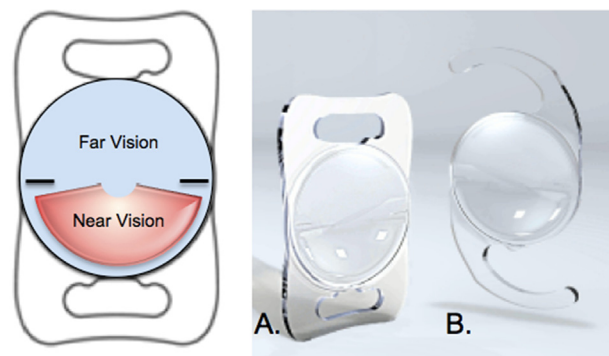
Postoperatively, patients were evaluated at 1 day, 1 week, and 1, 3, and 6 months. At each follow-up visit, the CDVA, UDVA, UNVA, refraction, and keratometry were measured. Trained optometrists performed follow-up visits at 70 consultation centers across the United Kingdom in standardized consultation rooms. Patients were requested to complete a computer-based patient satisfaction questionnaire at the 3-month postoperative visit.

### Intraocular Lens

The Lentis Mplus is a single-piece refractive multifocal IOL of hydrophilic acrylic with a hydrophobic surface. It has an inferior surface-embedded segment with a near addition (add) of +3.00 D. This IOL is based on the concept of rotational asymmetry, in which 2 radial sectors (1 for distance and 1 for near) are both on the optical axis of the IOL. Light is refracted to the near focus in 1 specific section only; the rest of the IOL is monofocal (Figure 1). Two models of the IOL are currently available; that is, the LS-312 with a C-loop haptic and the LS-313 with a plate haptic.

### Surgical Technique

The procedures were performed at 5 surgical centers across the U.K. by 7 experienced surgeons. Topical anesthesia (proxymetacaine hydrochloride 0.5%) was instilled, and



**Figure 1.** Distance and near sectors of the aspheric nonrotational symmetric multifocal IOL. A: Plate-haptic model. B: Model with C-loop haptic.

the patient was seated at the slitlamp, ensuring vertical head alignment. The corneal limbus was marked at the 270-degree position with a sterile disposable ink pen to ensure correct placement of the inferior reading section of the IOL. A sub-Tenon anesthetic block was given in all cases, and the patient was prepared and draped for surgery. Most incisions were made on the steepest corneal meridian to neutralize corneal astigmatism. After phacoemulsification, a foldable Mplus IOL was inserted in the capsular bag through a 2.75 mm corneal incision using the Viscoject 2.2 injector (Viscoject 2.2, Cartridge-Set LP604240M, Oculentis GmbH). Surgery in the second eye was usually performed 1 week later.

Postoperatively, patients were instructed to instill 1 drop of levofloxacin 0.5% (Oftaquix) 4 times daily for 2 weeks, 1 drop of dexamethasone 0.1% (Maxidex) 4 times daily for 2 weeks, and 1 drop of ketorolac trometamol 0.5% (Acular) 4 times daily for 1 month.

### Statistical Analysis

Data were analyzed in Microsoft Excel (Office 2010, Microsoft Corp.). Snellen visual acuity measurements were converted to logMAR equivalents to calculate the means and standard deviations.

## RESULTS

This study comprised 9366 eyes of 4683 consecutive patients. Of the eyes, 4240 received the C-loop IOL and 5126 received the plate-haptic IOL. The cohort comprised 2121 men (45.3%) and 2562 women (54.7%). The mean age of the patients at the time of surgery was 58 years  $\pm$  7.9 (SD) (range 20 to 84 years). Normal lens changes consistent with the patient's age were seen in 6294 eyes (67.2%), which had implantation of the IOL as a refractive procedure; 3025 eyes (32.3%) had cataract affecting CDVA and that was likely to progress; and 47 eyes (0.5%) had congenital cataract changes. The mean power of implanted IOLs was 22.5  $\pm$  5.0 D (range from 0.0 to 36.5 D). Of the 9366 eyes, 8426 were available 1 month postoperatively, 5276 at 3 months, and 4298 at 6 months.

**Refraction**

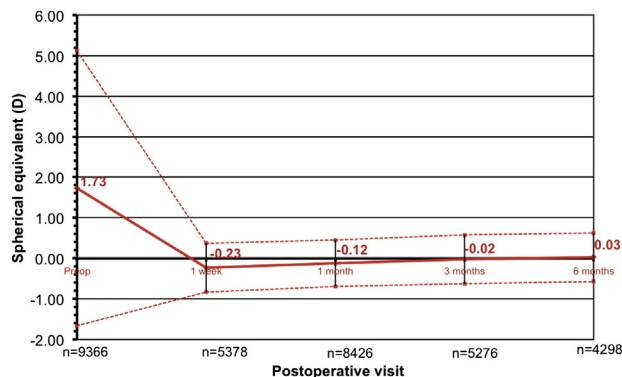
The mean preoperative sphere was  $+2.06 \pm 3.37$  D (range  $-17.50$  to  $+11.00$  D), decreasing to  $+0.24 \pm 0.61$  D and  $+0.29 \pm 0.61$  D at 3 months and 6 months, respectively. Figure 2 shows the stability of spherical equivalent (SE) up to 6 months postoperatively. The initially slightly myopic SE moved closer to zero 3 months and 6 months postoperatively, with a mean SE of  $-0.02 \pm 0.60$  D and  $+0.03 \pm 0.60$  D, respectively.

Figure 3 shows the predictability of SE 3 months postoperatively. The tight distribution of the SE values indicated high predictability, with an  $R^2$  value of 0.97. Of the eyes, 4844 (91.8%) were within  $\pm 1.00$  D of the SE.

**Visual Acuity**

Three months postoperatively, 4247 patients (80.5%) achieved a binocular UDVA of 6/6 (0.0 logMAR) and 5012 (95.0%) achieved 6/7.5 (0.1 logMAR) or better. Figure 4 shows the monocular and binocular cumulative UDVA. Six months postoperatively, 4285 patients (99.7%) had a binocular UDVA of 6/12 (0.3 logMAR) or better and 4156 (96.7%) had a monocular UDVA of 6/12 (0.3 logMAR) or better. The mean monocular UDVA was  $0.048 \pm 0.145$  logMAR and  $0.054 \pm 0.146$  logMAR at 3 months and 6 months, respectively.

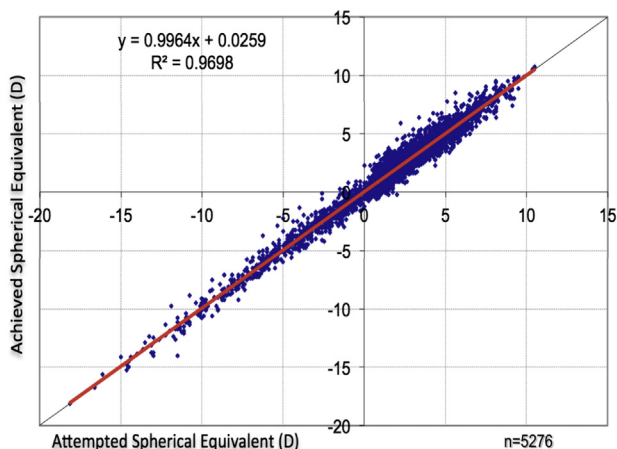
At 3 months, 1926 eyes (36.5%) had a UNVA of 6/7.5 (Jaeger [J]1) or better, 3298 (62.5%) had 6/9 (J2) or better, and 4390 (83.2%) had 6/12 (J3) or better monocularly. Bilaterally, 2707 patients (51.3%) had a UNVA of 6/7.5 (J1) or better, 4099 (77.7%) had 6/9 (J2) or better, and 4875 (92.4%) had 6/12 (J3) or better (Figure 5). The mean monocular UNVA was  $0.213 \pm$



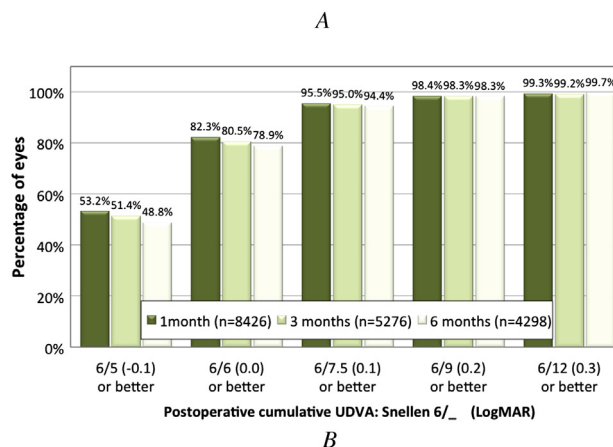
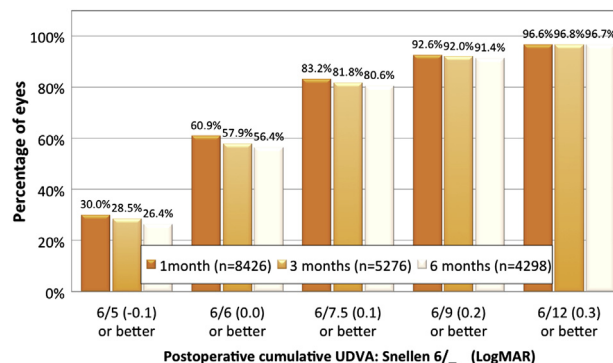
**Figure 2.** Stability of SE up to 6 months postoperatively. The solid red line represents the mean SE (SE = sphere + 0.5×cylinder). The dashed red line represents the standard deviation (n = number of eyes at each visit).

0.173 logMAR at 3 months and  $0.217 \pm 0.179$  logMAR at 6 months. The mean binocular UNVA was  $0.155 \pm 0.144$  logMAR and  $0.159 \pm 0.143$  logMAR, respectively.

The mean CDVA changed from  $-0.017 \pm 0.114$  logMAR preoperatively to  $-0.033 \pm 0.093$  logMAR at 3 months and  $-0.031 \pm 0.094$  logMAR at 6 months.



**Figure 3.** Predictability of SE 3 months postoperatively (attempted versus achieved SE). The red solid line represents the linear regression with slope of 0.9964 and intercept of +0.0259 (n = number of eyes; SE = sphere + 0.50×cylinder).



**Figure 4.** Monocular (A) and binocular (B) cumulative UDVA 1, 3, and 6 months postoperatively (UDVA = uncorrected distance visual acuity).

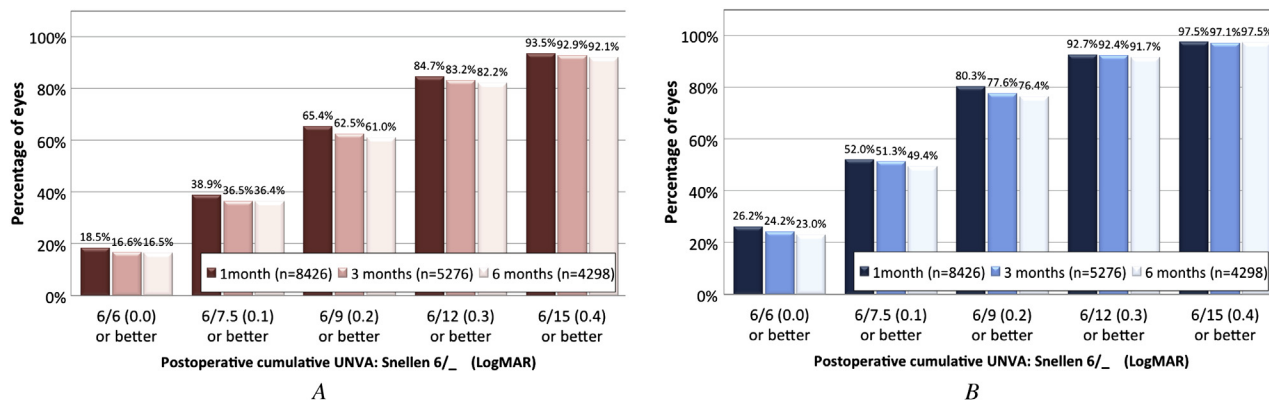


Figure 5. Cumulative monocular (A) and binocular (B) UNVA 1, 3, and 6 months postoperatively (UNVA = uncorrected near visual acuity).

**Intraocular Lens Exchange**

Eighty eyes required an IOL exchange (Table 1). Of these, 55 IOLs were exchanged because of patient reports of excessive glare and ghosting. In 41 eyes, IOL exchange in the dominant eye only was sufficient to alleviate symptoms. In 14 eyes (7 patients), IOL exchange in both eyes was required.

Late postoperative IOL tilt as a result of capsule fibrosis occurred in 25 eyes with the C-loop model. The C-loop model was discontinued in March 2011 and replaced with the plate-haptic model, which proved to be stable in the capsular bag with no cases of IOL tilt.

**Patient Satisfaction**

Table 2 shows the key questions related to the visual performance from a computer-based questionnaire 3 months postoperatively. The number of patients participating was 2173. The results show high patient satisfaction with only 37 (1.7%) being dissatisfied or very dissatisfied. Of the patients, 2038 (93.8%) reported they were very satisfied or satisfied with

the outcome of the procedure. Ability to read small print such as a telephone book, newspaper, or medicine bottle was significantly improved or improved in 1862 patients (85.7%).

Postoperative ability to drive at night was impaired in 474 patients and significantly impaired in 100 patients. This correlated with patients reporting moderate difficulty (424) and severe difficulty (154) with night vision due to starburst and halos around lights. Likewise, difficulty with night glare was moderate in 402 patients and severe in 124 patients.

**Adverse Events**

Table 3 shows the postoperative adverse events. The incidence of adverse events was lower than the incidence of adverse events in the U.S. Food and Drug Administration grid of historical controls for posterior chamber IOLs.

The CDVA was restored to 6/7.5 or better in all cases of retinal detachment. In the case of endophthalmitis, the UDVA recovered to 6/6 after successful treatment.

Cystoid macular edema (CME) was reported in 103 cases and successfully treated with the use of topical medications. Two eyes had persistent CME that required a course of bevacizumab (Avastin) injections.

**DISCUSSION**

Finding a multifocal IOL that can be used in a large population of patients is a challenge. In this study, Lentis Mplus multifocal IOL implantation after phacoemulsification provided excellent visual outcomes for distance and near vision in a high-volume practice. However, as with any multifocal IOL, severe night-vision phenomena might result in a small percentage of patients requiring an IOL exchange and would consequently not satisfy the patient's expectation of achieving spectacle independence for near

Table 1. Intraocular lens exchange in 9633 eyes.

Reason for Exchange/Eyes	New IOL
Glare/ghosting	
41 eyes (dominant eye only)	Lentis Mplus +1.50 reading add (23 eyes); monofocal (18 eyes)
14 eyes (bilateral IOL exchange)	Lentis Mplus +1.50 reading add (6 eyes); monofocal (8 eyes)
Lens tilt	
25 eyes (C-loop design only)	Lentis Mplus LS-313 (plate design) (20 eyes); existing IOL kept and repositioned with CTR (5 eyes)

CTR = capsular tension ring; IOL = intraocular lens

**Table 2.** Patient satisfaction 3 months postoperatively.

Question	Percentage
How satisfied are you with the outcome of your procedure?	
Very satisfied	68.1
Satisfied	25.7
Neither	4.5
Dissatisfied	1.2
Very dissatisfied	0.5
Would you recommend the procedure?	
Yes	97.5
No	2.5
How has your procedure affected your ability to drive at night?	
Significantly improved	19.6
Improved	23.1
Not affected	21.6
Impaired	21.8
Significantly impaired	4.6
I do not drive	9.3
How has your procedure affected your ability to read small print such as a telephone book, newspaper, or medicine bottle?	
Significantly improved	59.2
Improved	26.5
Not affected	6.7
Impaired	6.6
Significantly impaired	1.0
How much difficulty do you now have with your vision at night because of starburst or halos around bright lights?	
No difficulty	32.5
A little difficulty	40.9
Moderate difficulty	18.5
Severe difficulty	7.1
How much difficulty do you now have with your vision at night because of glare from bright light?	
No difficulty	32.7
A little difficulty	43.2
Moderate difficulty	18.5
Severe difficulty	5.7

and distance vision. Careful preoperative counseling is necessary for all patients having multifocal IOL implantation.

Cataract or refractive lens exchange (RLE) with the Lentis Mplus IOL proved to be predictable, with a mean SE of  $-0.02 \pm 0.60$  D at 3 months and  $+0.03 \pm 0.60$  D at 6 months. This is a very good outcome considering the wide range of refraction in our group of patients (sphere range  $-17.5$  to  $+11.0$  D); the implanted IOL power range was 0.0 to 36.5 D.

No multifocal IOL design to date is without night-vision phenomena. In our study, 154 patients (7.1%)

**Table 3.** Adverse events in the study cohort compared with the FDA grid of historical controls for posterior chamber IOL.

Adverse Event	Percentage	
	FDA Grid	9366 Mplus IOLs
Cumulative hyphema	2.2	0.01
Cumulative macular edema	3.0	1.1
Cumulative retinal detachment	0.3	0.04
Cumulative pupillary block	0.1	0.0
Cumulative IOL dislocation	0.1	0.04
Cumulative endophthalmitis	0.1	0.01
Cumulative hypopyon	0.3	0.0
Cumulative surgical reintervention	0.8	0.5
Persistent macular edema	0.5	0.02
Persistent corneal edema	0.3	0.05
Persistent iritis	0.3	0.0
Persistent raised IOP requiring treatment	0.4	0.01

Cumulative = adverse events that occurred at any time during postoperative care; FDA = U.S. Food and Drug Administration; IOL = intraocular lens; IOP = intraoperative pressure; Persistent = adverse events that persisted 1 year postoperatively

experienced severe halo and starburst symptoms and 124 (5.7%) rated their glare at night as severe 3 months postoperatively. Considering the questionnaire was distributed 3 months postoperatively, the rates might reduce with neuroadaptation and correction of ametropia in patients with remaining refractive error. However, self-reported patient satisfaction was very high, with 2119 patients (97.5%) willing to recommend this procedure. Forty-eight patients were dissatisfied to the point that the multifocal IOLs had to be explanted in 1 eye or both eyes.

A thorough metaanalysis of multifocal IOLs was performed by Cochener et al.<sup>4</sup> comparing literature on different types of multifocal IOLs published since 2000. The study found the mean UDVA of all multifocal IOLs to be 0.093 logMAR. When analyzing different types of multifocal IOLs, the mean UDVA was 0.105 logMAR for diffractive IOLs, 0.085 logMAR for refractive IOLs, and 0.067 logMAR when the Restor IOL (Alcon Laboratories, Inc.) was analyzed separately. In our study, the mean monocular UDVA was 0.048 logMAR and 0.054 logMAR at 3 months and 6 months, respectively, which is a slightly better result than previously published findings. However, a significant portion of our patients (67.2%) had IOL implantation as a RLE procedure rather than a cataract procedure and started off with good levels of CDVA.

The same metaanalysis<sup>4</sup> compared the UNVA between different multifocal IOL types. Diffractive IOLs performed better than refractive IOLs, with a mean UNVA of 0.082 logMAR for diffractive IOLs

and 0.217 logMAR for refractive IOLs. A separate analysis of the Restor IOL showed a mean UNVA of 0.064 logMAR. Our results with the Lentis Mplus IOL are similar to the performance of refractive IOLs, with a mean monocular UNVA of 0.217 logMAR and a mean binocular UNVA of 0.159 logMAR 6 months postoperatively.

The distance vision achieved with the Lentis Mplus was comparable to that with other multifocal IOLs, although the near vision was worse than that with diffractive and hybrid-diffractive multifocal IOLs.<sup>8,10-17</sup>

The main limitation of our study was an absence of data on intermediate visual acuity. Several publications have confirmed excellent intermediate vision with this rotationally asymmetric IOL.<sup>21-30</sup> Muñoz et al.<sup>27</sup> evaluated 32 patients who had bilateral implantation of the Lentis Mplus LS-312 MF30 IOL and found intermediate visual acuity of at least 6/12 in 76% of eyes at 3 intermediate distances (70 cm, 1 m, and 2 m). McAlinden and Moore<sup>22</sup> combined the Lentis Mplus IOL with a +1.50 D near add in the dominant eye and +3.00 near add in the nondominant eye and found a mean intermediate visual acuity at 66 cm of M0.89 (approximately 0.35 logMAR). Ramón et al.<sup>23</sup> analyzed 26 eyes of 13 patients with binocular Lentis Mplus IOLs with a +3.00 D near add and found a good range of vision at defocus levels equivalent to intermediate vision, with a mean value of 0.3 logMAR.

Previous studies compared the performance of the Lentis Mplus IOL with that of some commonly used multifocal IOLs. Alió et al.<sup>29</sup> compared the Lentis Mplus LS-312 MF30 with the Acri.Lisa 366D (Zeiss) diffractive IOL. Intermediate vision and contrast sensitivity were better with the Lentis Mplus. However, the Acri.Lisa provided better distance and near visual outcomes. van der Linden et al.<sup>25</sup> compared the Lentis Mplus LS-312 MF30 with the Restor SN6AD1 IOL. They found that the IOLs achieved comparable distance vision, while the Restor provided better near visual acuity. A similar comparison of the Lentis Mplus and the Restor IOL was performed by Alfonso et al.<sup>28</sup> and Alió et al.<sup>30</sup> Both studies found that near vision was better with the Restor IOL. Intermediate vision was better with the Lentis Mplus in 1 study<sup>30</sup> and no different than that with the Restor IOL in the other study.<sup>28</sup>

The main advantage of the asymmetric design of the Lentis Mplus IOL over traditional rotationally symmetrical multifocal IOLs is the presence of only 1 transition zone between the aspheric distance vision zone and the inferior sector-shaped near-vision zone. This technology should in theory reduce the source of scattering and aberrations, minimize halos and glare, and improve contrast sensitivity. Unfortunately, we did not evaluate contrast sensitivity in this retrospective study. Alió et al.<sup>21</sup> compared contrast sensitivity

between a monofocal IOL and the Lentis Mplus LS-312 MF30 IOL and found no difference in contrast sensitivity under scotopic or mesopic conditions between the 2 IOLs. However, when comparing optical aberrations, the Lentis Mplus IOL had a significantly higher amount of primary coma, which could be due to the geometry of the IOL and its asymmetric design. According to the authors, primary vertical coma found in this study could be responsible for the excellent depth of focus with the Lentis Mplus IOL but could also have a negative impact on visual quality. Similar findings of induced primary vertical coma were confirmed by other studies<sup>23,29</sup>; however, IOL tilt with the C-loop design (LS-312) might have also been responsible for the increase in coma. The new plate-haptic design of the Lentis Mplus (LS-313) should reduce IOL tilt-related coma. Muñoz et al.<sup>27</sup> found distance contrast sensitivity with the Lentis Mplus IOL to be similar to that with monofocal IOLs under photopic conditions. Photopic near contrast sensitivity and mesopic distance contrast sensitivity values were also similar between the Lentis Mplus IOL and a monofocal IOL except at high frequencies. The same findings for contrast sensitivity were found in a comparison between a monofocal IOL combination and a combination of the Lentis Mplus LS-312 MF30 IOL in 1 eye and the Acri.Lisa 366 diffractive IOL in the second eye.<sup>26</sup> However, contrast sensitivity in this study was evaluated binocularly for the IOL combination, not for each IOL separately.

Alió et al.<sup>29</sup> compared the contrast sensitivity of the Lentis Mplus LS-312 IOL and the Acri.Lisa 366D diffractive IOL and found significantly better values in photopic contrast sensitivity at high spatial frequencies with the Lentis Mplus IOL. Alfonso et al.<sup>28</sup> compared contrast sensitivity of the Lentis Mplus LS-312 MF30 IOL and the Acrysof Restor SN6AD1 (+3.00 near add). Contrast sensitivity seemed to be statistically significantly better with the Restor IOL under photopic conditions but no different under mesopic conditions. On the other hand, Alió et al.<sup>30</sup> compared the Lentis Mplus IOL with the Restor SN6AD3 IOL (+4.00 near add) and found photopic contrast sensitivity was significantly better with the Lentis Mplus IOL. A larger scale study would be required to establish whether the new technology of the Lentis Mplus IOL provides better contrast sensitivity than previous multifocal IOLs.

In summary, the new-generation Lentis Mplus multifocal IOL restored distance visual function and improved near visual acuity. The main limitation of this retrospective study is that only a limited number of variables can be retrieved when working with such a large amount of data. It would be useful to evaluate near visual acuity with distance correction to assess

the true performance of the IOL for near vision. Intermediate visual acuity and contrast sensitivity evaluation on a large scale would also be valuable.

### WHAT WAS KNOWN

- Multifocal IOLs developed over the past 2 decades are effective at correcting distance and near visual acuity. The recently developed Lentis Mplus IOL brings a new concept and design of a multifocal IOL. A few publications evaluated benefits and drawbacks of this new concept.


### WHAT THIS PAPER ADDS

- This study is the first to publish performance of the Lentis Mplus IOL in a large patient cohort.
- This IOL proved to be safe and effective in a large population, achieving high patient satisfaction and a low IOL exchange rate.

### REFERENCES

- Bellucci R. Multifocal intraocular lenses. *Curr Opin Ophthalmol* 2005; 16:33–37
- Lane SS, Morris M, Nordan L, Packer M, Tarantino N, Wallace RB III. Multifocal intraocular lenses. *Ophthalmol Clin North Am* 2006; 19(1):89–105
- Buznego C, Trattler WB. Presbyopia-correcting intraocular lenses. *Curr Opin Ophthalmol* 2009; 20:13–18
- Cochener B, Lafuma A, Khoshnood B, Courouve L, Berdeaux G. Comparison of outcomes with multifocal intraocular lenses: a meta-analysis. *Clin Ophthalmol* 2011; 5:45–55. Available at: <http://www.ncbi.nlm.nih.gov/pmc/articles/PMC3033003/pdf/oph-5-045.pdf>. Accessed April 15, 2013
- Walkow T, Liekfeld A, Anders N, Pham DT, Hartmann C, Wollensak J. A prospective evaluation of a diffractive versus a refractive designed multifocal intraocular lens. *Ophthalmology* 1997; 104:1380–1386
- Montés-Micó R, España E, Bueno I, Charman WN, Menezo JL. Visual performance with multifocal intraocular lenses; mesopic contrast sensitivity under distance and near conditions. *Ophthalmology* 2004; 111:85–96
- Alió JL, Tavalato M, De La Hoz F, Claramonte P, Rodríguez-Prats J-L, Galal A. Near vision restoration with refractive lens exchange and pseudoaccommodating and multifocal refractive and diffractive intraocular lenses; comparative clinical study. *J Cataract Refract Surg* 2004; 30:2494–2503
- Schmidinger G, Simader C, Dejaco-Ruhsurm I, Skorpik C, Pieh S. Contrast sensitivity function in eyes with diffractive bifocal intraocular lenses. *J Cataract Refract Surg* 2005; 31:2076–2083
- Dick HB. Accommodative intraocular lenses: current status. *Curr Opin Ophthalmol* 2005; 16:8–26
- Kohnen T, Allen D, Boureau C, Dublineau P, Hartmann C, Mehdorn E, Rozot P, Tassinari G. European multicenter study of the AcrySof ReSTOR apodized diffractive intraocular lens. *Ophthalmology* 2006; 113:578–584
- Pepose JS, Qazi MA, Davies J, Doane JF, Loden JC, Sivalingham V, Mahmoud AM. Visual performance of patients with bilateral vs combination Crystalens, ReZoom, and ReSTOR intraocular lens implants. *Am J Ophthalmol* 2007; 144:347–357
- Żelichowska B, Rekas M, Stankiewicz A, Cerviño A, Montés-Micó R. Apodized diffractive versus refractive multifocal intraocular lenses: optical and visual evaluation. *J Cataract Refract Surg* 2008; 34:2036–2042
- Alió JL, Elkady B, Ortiz D, Bernabeu G. Clinical outcomes and intraocular optical quality of a diffractive multifocal intraocular lens with asymmetrical light distribution. *J Cataract Refract Surg* 2008; 34:942–948
- Maxwell WA, Cionni RJ, Lehmann RP, Modi SS. Functional outcomes after bilateral implantation of apodized diffractive aspheric acrylic intraocular lenses with a +3.0 or +4.0 diopter addition power; randomized multicenter clinical study. *J Cataract Refract Surg* 2009; 35:2054–2061
- Kohnen T, Nuijts R, Levy P, Haefliger E, Alfonso JF. Visual function after bilateral implantation of apodized diffractive aspheric multifocal intraocular lenses with a +3.0 D addition. *J Cataract Refract Surg* 2009; 35:2062–2069
- de Vries NE, Webers CAB, Montés-Micó R, Ferrer-Blasco T, Nuijts RMMA. Visual outcomes after cataract surgery with implantation of a +3.00 D or +4.00 D aspheric diffractive multifocal intraocular lens: comparative study. *J Cataract Refract Surg* 2010; 36:1316–1322
- Lane SS, Javitt JC, Nethery DA, Waycaster C. Improvements in patient-reported outcomes and visual acuity after bilateral implantation of multifocal intraocular lenses with +3.0 diopter addition: multicenter clinical trial. *J Cataract Refract Surg* 2010; 36:1887–1896
- Mesci C, Erbil HH, Olgun A, Yaylali SA. Visual performances with monofocal, accommodating, and multifocal intraocular lenses in patients with unilateral cataract. *Am J Ophthalmol* 2010; 150:609–618
- Woodward MA, Randleman JB, Stulting RD. Dissatisfaction after multifocal intraocular lens implantation. *J Cataract Refract Surg* 2009; 35:992–997
- de Vries NE, Webers CAB, Touwslager WRH, Bauer NJC, de Brabander J, Berendschot TT, Nuijts RMMA. Dissatisfaction after implantation of multifocal intraocular lenses. *J Cataract Refract Surg* 2011; 37:859–865
- Alió JL, Piñero DP, Plaza-Puche AB, Rodríguez Chan MJ. Visual outcomes and optical performance of a monofocal intraocular lens and a new-generation multifocal intraocular lens. *J Cataract Refract Surg* 2011; 37:241–250
- McAlinden C, Moore JE. Multifocal intraocular lens with a surface-embedded near section: short-term clinical outcomes. *J Cataract Refract Surg* 2011; 37:441–445
- Ramón ML, Piñero DP, Pérez-Cambrodí RJ. Correlation of visual performance with quality of life and intraocular aberrometric profile in patients implanted with rotationally asymmetric multifocal IOLs. *J Refract Surg* 2012; 28:93–99
- Alió JL, Plaza-Puche AB, Piñero DP, Javaloy J, Ayla MJ. Comparative analysis of the clinical outcomes with 2 multifocal intraocular lens models with rotational asymmetry. *J Cataract Refract Surg* 2011; 37:1605–1614
- van der Linden JW, van Velthoven M, van der Meulen I, Nieuwendaal C, Mourits M, Lapid-Gortzak R. Comparison of a new-generation sectorial addition multifocal intraocular lens and a diffractive apodized multifocal intraocular lens. *J Cataract Refract Surg* 2012; 38:68–73
- Muñoz G, Albarrán-Diego C, Javaloy J, Sakla HF, Cerviño A. Combining zonal refractive and diffractive aspheric multifocal intraocular lenses. *J Refract Surg* 2012; 28:174–181
- Muñoz G, Albarrán-Diego C, Ferrer-Blasco T, Sakla HF, García-Lázaro S. Visual function after bilateral implantation of a new

- zonal refractive aspheric multifocal intraocular lens. J Cataract Refract Surg 2011; 37:2043–2053
28. Alfonso JF, Fernández-Vega L, Blázquez JI, Montés-Micó R. Visual function comparison of 2 aspheric multifocal intraocular lenses. J Cataract Refract Surg 2012; 38:242–248
29. Alió JL, Plaza-Puche AB, Javaloy J, Ayala MJ, Moreno LJ, Piñero DP. Comparison of a new refractive multifocal intraocular lens with an inferior segmental near add and a diffractive multifocal intraocular lens. Ophthalmology 2012; 119:555–563
30. Alió JL, Plaza-Puche AB, Javaloy J, Ayala MJ. Comparison of the visual and intraocular optical performance of a refractive multifocal IOL with rotational asymmetry and an apodized diffractive multifocal IOL. J Refract Surg 2012; 28:100–105
31. Retzlaff JA, Sanders DR, Kraff MC. Development of the SRK/T intraocular lens implant power calculation formula. J Cataract Refract Surg 1990; 16:333–340; correction, 528



First author:

Jan A. Venter, MD

*Private clinic, London,  
United Kingdom*